



PATIENT

Sadie Colwell

SPECIES

Canine

BREED

German Shepherd Mix

SEX

Female Spayed

AGE

2.14.12

WEIGHT

60.4lbs

INTERPRETED BY

Maggie Machen Lamy,
DVM, DACVIM
(Cardiology)

HOSPITAL NAME

DocSide Veterinary
Medical Center

REFERRING VET

Dr. Tierney

INVOICE

31275

DATE

6.18.23

PRESENTING CLINICAL SIGNS

History: Recheck echo. Grade II-III/VI systolic murmur. Patient is aggressive in office.

-Current medications: Heart Gard and Simparica for preventatives. Vetmedin 5mg PO SID

-Sedation used: Not required to complete full diagnostic ultrasound.

-Pertinent previous ultrasound results (6/2022 MML): mod to severe MR, mod LAE, mild LVE, trivial TR; LA 3.2, LV 4.9

-STAT: Not requested

-Imaging performed by: Andi Parkinson, BS, RDMS.

RADIOGRAPHIC FINDINGS *NOTE: Images submitted for supplemental information only.

Mild cardiomegaly. No obvious evidence of CHF.

ECHOCARDIOGRAM FINDINGS

2D, m-mode, color flow and doppler imaging is available. Diffuse thickening of mitral valve leaflets (anterior>posterior) with minimal prolapse into the left atrial lumen. Moderate to severe eccentric mitral regurgitation with moderate left atrial dilation. Normal MR velocity. Mildly increased LV diameter with adequate myocardial function. The tricuspid valve appears mildly thickened with trivial tricuspid regurgitation. Normal right atrial and ventricular diameter. The pulmonic and aortic valves are normal in morphology and mobility. Normal pulmonic and aortic outflow velocities. No aortic and trivial pulmonic insufficiency. No pericardial or pleural effusion noted. No cardiac tumors observed.

CARDIAC CHART

| CANINE CARDIAC PARAMETERS | MR VMAX (m/s) | TR VMAX (m/s) | LA/AO (Boon method) | LA/AO (Heart Base; Swe) | FS (%) | EF (%) | EPSS (cm) |
|--|---------------|---------------|---------------------|-------------------------|---------------------------------|--|--|
| NORMAL PARAMETER | 4.5-5.5 | <2.7 | 1.3 | <1.6 | 28-40 | 40-100 | <0.6 |
| PATIENT | 4.5 | | NM | 1.7 | | | NM |
| CANINE CARDIAC PARAMETERS | HR (BPM) | AV VMAX (m/s) | PV MAX (m/s) | BODY WEIGHT (kg) | LA 2D short axis Base view (cm) | LVIDd Avg; 2D and m-mode short axis (cm) | LVIDs Avg; 2D and m-mode short axis (cm) |
| NORMAL PARAMETER | 50-100 | 0.7-1.7 | 0.7-1.6 | BELOW | BELOW | BELOW | BELOW |
| PATIENT | | 0.8 | | 27 | 3.5 | | |
| *Normal chamber parameters expressed as a mean value (SD) | | | | 3 | 1.27 (5.3) | 2.46 (2.46) | 1.36 (5.5) |
| BODY WEIGHT DEPENDENT PARAMETERS | | | | 5 | 1.40 (4.5) | 2.74 (5.2) | 1.60 (4.7) |
| *Note: All measurements based upon multi-modal images and methods. An average value is reported. | | | | 10 | 1.50 (3.8) | 3.27 (3.5) | 2.06 (3.1) |
| | | | | 15 | 1.83 (2.0) | 3.71 (2.4) | 2.43 (2.1) |
| | | | | 20 | 2.02 (1.9) | 4.14 (2.2) | 2.80 (2.0) |
| | | | | 25 | 2.18 (2.4) | 4.48 (2.9) | 3.10 (2.5) |
| | | | | 30 | 2.33 (3.3) | 4.83 (3.9) | 3.39 (3.4) |
| | | | | 35 | 2.48 (4.3) | 5.17 (5.0) | 3.69 (4.5) |
| | | | | 40 | 2.62 (5.2) | 5.48 (6.1) | 3.96 (5.4) |
| | | | | 50 | 2.88 (7.1) | 6.07 (8.3) | 4.46 (7.4) |

Adapted from June Boon, Veterinary Echocardiography, 1998
Rishniw M and Hollis NE, J Vet Intern Med 2000; 14:429-435
Hansson et al, Vet Rad and Ultrasound 2002
Bonagura et al. Echocardiography: principles of interpretation, Vet Clin North Am 15:1177, 1995

INTERPRETATION OF THE FINDINGS & FURTHER RECOMMENDATIONS

Compared to the prior study, findings are similar. Moderate to severe mitral regurgitation is unchanged, without significant progression in left heart dimensions. Persistently moderate left atrial enlargement indicates there is relatively low risk for imminent complication, however risk for progression to spontaneous congestive heart failure in the future is elevated. No additional issues are identified.

Recommend continue Pimobendan lifelong with no obvious indication for additional medications. Continued assessment of progression in the future will help predict long term outcome, however prognosis remains guarded at this stage (B2). A lack of progression over serial studies is certainly a good sign.

Omega fatty acid supplementation and mild salt restriction may also be of some long-term benefit. Monitor for development of a progressive cough, labored breathing, exercise intolerance or collapse episodes.

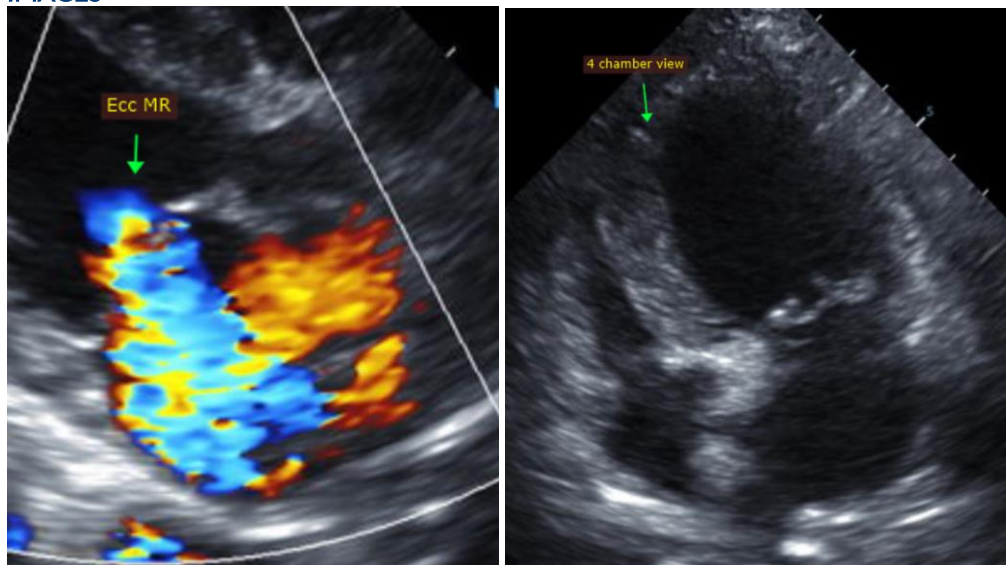
Anesthetic risk is considered mildly elevated. Cardiac protective drug choices (opioid/benzodiazepine premedication, Propofol or alfaxalone induction, iso or sevo gas) are recommended. Monitor for arrhythmias, hypotension, and hypoxia both intra and post-operatively and intervene as necessary. Judicious IV fluid rates are recommended to avoid fluid overload. Avoid heart rate stimulating drugs such as atropine unless clinically indicated. **Ideally, I would avoid Dexdomitor in this patient going forward. Alfaxalone can be utilized as a more cardiac protective alternative.**

PLAN

Baseline BP recommended q 6mo. Continue heart muscle support Pimobendan 0.25-0.3mg/kg PO q12h.

Recommend monitor for progression with a recheck echocardiogram in 6 months, sooner if any development of clinical signs.

IMAGES



The information and recommendations provided are based on the images presented by the referring veterinarian. No evaluation can be communicated regarding pathology that was not visible in the image/video clips provided.

Thank you for this referral. This report was generated using transcription software, and minor dictation errors may be present. If the clinical or image interpretation does not parallel your findings or if I can be of any further assistance please contact me.

Maggie Machen Lamy, DVM
Diplomate of the American College of Veterinary Internal Medicine (Cardiology)
info@sonopath.com